Foreign Body Reactions 94

M. Abdel Rahim Abdallah, Mahmoud M.A. Abdallah and Marwa Abdallah

Chapter Contents

General Considerations 1681
Foreign Body Reactions to Inorganic and Metallic Compounds. 1683
Reactions to Organic and Biologic Products 1688
Injectable Soft Tissue Fillers 1689
Miscellaneous. 1690

Key features

- Foreign body reactions represent inflammatory responses to inorganic and high-molecular-weight organic materials that have been introduced into the skin and are variably resistant to degradation
- Routes of introduction can vary from accidental or self-inflicted to surgical and cosmetic procedures to topical application of various compounds
- The most common clinical presentation is red to red–brown papules, nodules, or plaques (with or without ulceration) that are due to granulomatous inflammation
- Less common clinical presentations include lichenoid and pseudolymphomatous lesions, or the development of a fistula or draining wound
- Histopathologic findings vary from granulomas (foreign body, sarcoidal, palisading) to lichenoid, eczematous, or pseudolymphomatous patterns
- Diagnosis of foreign body reactions requires a high index of suspicion, thorough history, recognition of distinctive distribution patterns, and histologic examination (including polarized microscopy)

GENERAL CONSIDERATIONS

Definition

Literally, any material – living or non-living – introduced into the body is a "foreign body" and is treated by our immune system as "non-self" in order to elicit an appropriate response. Such a broad definition also includes infectious agents, but they are covered elsewhere (see Chs. 74–85). This chapter will focus on non-living materials that have been introduced into the dermis or subcutis[1–3]. They represent inorganic compounds or organic material of high molecular weight (or their products) that resist degradation by the body's inflammatory cells. Although granulomatous reaction patterns are most commonly observed, there is a broad range of clinicopathologic presentations. Foreign bodies reported to elicit skin reactions are listed in Table 94.1.

Routes of Entry

Accidental

Inoculation with foreign bodies may occur unintentionally during various activities such as gardening (wood splinters, cactus spines) or swimming and diving (coelenterate envenomation, sea urchin spines), or it may result accidentally, such as in a blast injury (silica particles) or motor vehicle accident.

Surgical procedures

Contamination of wounds by talc or starch powders used for lubrication of surgical gloves may incite a foreign body reaction. Surgical sutures also cause a foreign body response and this is routinely seen in surgical re-excisions (see Fig. 151.19). In addition, foreign body reactions have been observed in association with 2-octyl cyanoacrylate, a tissue adhesive used for small superficial wounds and lacerations, as well as a copolymer-containing lubricating agent used for liposuction[4].

Iatrogenic

Foreign material implanted into the skin for the purpose of tissue augmentation, e.g. injectable soft tissue fillers, can induce reactions in some individuals (Fig. 94.1). Paraffin is still being used illegally for tissue augmentation (see below), and a paraffin foreign body reaction can also occur after the application of paraffin-containing materials such as nasal packs[5].

Tattooing

Tattooing is the introduction of an exogenous pigment into the dermis, either deliberately or accidentally, resulting in permanent discoloration of the skin.

Topical application

When applied to the skin surface, antiperspirant and antipruritic preparations that contain zirconium oxide or zirconium lactate were noted to cause foreign body reactions. As a result, zirconium lactate was generally banned in 1978 (see below). These zirconium compounds have subsequently been replaced by aluminum–zirconium complexes and while the latter are less sensitizing, they may occasionally lead to foreign body reactions[6].

Self-inflicted

Self-administered intravenous and subcutaneous injections, a common practice among individuals with substance use disorder, may lead to the introduction of foreign material into the skin. An example is the injection of crushed talc-containing tablets.

Pathogenesis

The initial tissue response to most foreign substances involves an accumulation of neutrophils, which usually fail to properly deal with the foreign body. Its persistence attracts monocytes and local tissue macrophages that engulf the foreign material and become activated. Engulfed material may resist degradation and remain sequestered within the macrophages. Activated macrophages secrete a variety of specific biologically active substances, e.g. cytokines and chemokines, that attract additional macrophages and blood monocytes. The formation of a chronic granuloma represents an attempt by the body to sequester a persistent indigestible material. Individual macrophages may become larger (epithelioid histiocytes) or fuse to form multinucleated foreign body giant cells (Fig. 94.2)[7]. The infiltrate also contains T lymphocytes and fibroblasts. The pathogenesis of other patterns of reactions, e.g. lichenoid, pyogenic granuloma-like, pseudolymphomatous, remains speculative.

Clinical Features

The host response and, consequently, the clinical presentations of foreign body implantation are variable (Table 94.2 & 94.3). An acute inflammatory response occurs shortly after the entry of the foreign material. This may resolve, to be followed weeks, months, or even years later by a chronic inflammatory response. Although the latter may have a variety of clinical presentations, red to red–brown papules, nodules, and plaques (with or without ulceration) are most commonly observed. Over time, the lesions may become firmer due to fibrosis. The pattern

Downloaded for Anonymous User (n/a) at Egyptian Knowledge Bank from ClinicalKey.com by Elsevier on March 10, 2024. For personal use only. No other uses without permission. Copyright ©2024. Elsevier Inc. All rights reserved.

CLASSIFICATION OF FOREIGN BODIES ACCORDING TO THEIR ORIGINS AND ROUTES OF ENTRY		
Origin		**Route of entry**
Non-biologic (inorganic/metallic compounds)		
	Tattoo inks	Decoration Cosmetic Accidental Iatrogenic
	Ferrous subsulfate (Monsel's solution)	Hemostasis (iatrogenic)
	Paraffin	Tissue augmentation Iatrogenic
	Silicone (polydimethyl siloxane) liquid or gel	Tissue augmentation
	Silica	Wound contamination Blast injuries
	Talc	Surgical procedures Wound contamination Umbilical stump contamination Intravenous injection of self-prepared drugs
	Zirconium	Topical application: antiperspirants
	Beryllium	*Local cutaneous:* Laceration by broken fluorescent lamps (historical) *Systemic:* Penetration of intact skin by fine particles (<1 micron) Inhalation
	Aluminum	Subcutaneous injection of aluminum-containing vaccines
	Zinc	Subcutaneous injection of insulin–zinc preparations
	Other synthetic fillers, e.g. poly-L-lactic acid, calcium hydroxylapatite, polymethylmethacrylate	Tissue augmentation
Biologic		
Produced in the skin but normally isolated from body's immune surveillance	Hair keratin (see Ch. 38)	Ruptured follicle or cyst* Ingrown hair Pilonidal sinus Interdigital pilonidal sinus (hairdressers, barbers, dog groomers)
	Nail keratin	Ingrown nail
Produced by other living organisms	Starch	Surgical procedures, plasma expander
	Cactus spines	Accidental Occupational
	Jellyfish and corals	Accidental Swimming or diving
	Sea urchin spines (see Ch. 85)	Accidental Swimming or diving
	Silk sutures	Surgical procedures
	Hyaluronic acid	Tissue augmentation
	Bovine collagen†	Tissue augmentation
Miscellaneous	Corticosteroids	Intralesional injection
	Sutures, primarily absorbable (rarely nylon or polypropylene)	Surgical procedures
	Polyamide synthetic "hair" fibers	Scalp "hair" restoration
	2-octyl cyanoacrylate	Tissue adhesive for small, superficial wounds and lacerations
	Hydrophilic polymer and potassium ferrate (WoundSeal® powder)	Hemostasis
	Vitamin C serum	Via microneedling for rejuvenation

*Most common cause of a foreign body reaction in the skin.
†The only commercially available filler in the US that contains collagen also contains polymethylmethacrylate (PMMA) microspheres (Bellafill®).

Table 94.1 Classification of foreign bodies according to their origins and routes of entry.

and arrangement of the cutaneous lesions will correspond to the route of inoculation, and observation of this patterning, in association with a relevant patient history, is crucial.

In addition to nodules and plaques, other forms of foreign body reaction include pyogenic granuloma-like lesions[8], lichenoid lesions[9,10], and a chronic draining fistula or wound[11,12].

Pathology

Apart from the acute reaction to the trauma that accompanies the introduction of the foreign body, a chronic reaction is the usual response. Although different patterns of chronic local tissue reactions have been described, including lichenoid[9], eczematous, and pseudolymphomatous[13], the most common is the granulomatous type of reaction[7,14]

Downloaded for Anonymous User (n/a) at Egyptian Knowledge Bank from ClinicalKey.com by Elsevier on March 10, 2024. For personal use only. No other uses without permission. Copyright ©2024. Elsevier Inc. All rights reserved.

Fig. 94.1 Foreign body reaction at site of bovine collagen injection. Formation of granulomas at bovine collagen injection sites occurs in ~1% of patients who have had two negative skin tests.

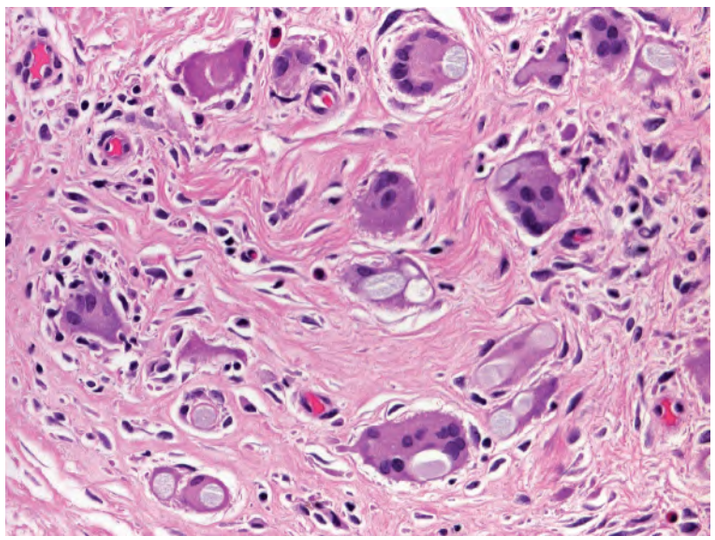

Fig. 94.2 Foreign body reaction to sutures. The foreign bodies have been engulfed primarily by foreign body-type giant cells; one Langhans-type giant cell is present at 12 o'clock. *Courtesy Lorenzo Cerroni, MD.*

(see Table 94.3). Granulomas that develop as a reaction to foreign bodies are of two major types:

- allergic (immunologic)
- non-allergic ("foreign body").

The allergic type is characterized by the presence of collections of individual epithelioid histiocytes associated with variable numbers of lymphocytes and fewer multinucleated Langhans-type giant cells[7]. In the non-immunologic type, the foreign body giant cell is the most conspicuous component of the infiltrate (see Fig. 94.2), which also contains histiocytes, lymphocytes, and other inflammatory cells[14].

A histologic decision as to whether a granuloma is of the foreign body type or of the allergic type is not always possible and different patterns may be seen in the same section. The foreign material inciting a reaction may be detected in conventional H&E-stained sections or may require special procedures for its identification (see Table 94.3).

Diagnosis

Foreign body reactions should be considered in the differential diagnosis of localized inflammatory nodules and plaques, especially when there is a persistent draining wound or sinus. Occasionally, these reactions present as pyogenic granulomas or localized lichenoid papules. Clinical morphology is usually not distinctive, but there may be a suggestive distribution pattern, and a thorough history is indispensable for arriving at the correct diagnosis.

Histopathologic examination can confirm the granulomatous nature of a lesion and occasionally foreign bodies may show distinctive microscopic features in H&E-stained sections (Fig. 94.3)[14]. Because some foreign bodies are better visualized via polarized microscopy, this is routinely performed (Fig. 94.4). In addition to detecting radiolucent foreign bodies, high frequency ultrasound has been employed to assess the severity and depth of inflammatory reactions to tattoos and soft tissue fillers[14]. CT, MRI, and PET-CT have also been used to evaluate foreign body reactions but can have limitations with regard to detection of small cutaneous foreign bodies.

Identification of the chemical nature of the foreign body requires sophisticated physicochemical procedures (e.g. energy-dispersive X-ray analysis, laser-induced breakdown spectroscopy) that are available in only a few research centers[15].

To summarize, accurate identification of a foreign body reaction depends on a high index of suspicion, thorough history-taking, and histologic examination, including polarized microscopy.

CLINICAL PRESENTATIONS OF FOREIGN BODY REACTIONS	
Clinical presentation	**Foreign substance**
Erythema, induration, papules, nodules, plaques (with or without ulceration)	Tattoo inks, paraffin, silicone*, silica*, beryllium (local), starch, soft tissue fillers (e.g. hyaluronic acid)
Sarcoidosis-like granulomatous papules	Tattoo inks, talc, zirconium, beryllium (systemic), soft tissue fillers (e.g. hyaluronic acid, bovine collagen)
Pyogenic granuloma-like lesions	Talc, keratin (ingrown nail)
Pseudofolliculitis barbae, "ingrown" hairs of the pubic region and upper thighs	Keratin
Pruritic lichenoid papules and plaques (often in an irregular linear pattern)	Tattoo inks, jellyfish and coral stings
Abscess	Keratin (e.g. pilonidal sinus), zinc, paraffin, soft tissue fillers
Sinus tract/fistula	Suture, keratin (pilonidal sinus, interdigital pilonidal sinus [barbers, hairdressers])
Persistent subcutaneous nodules at injection site	Aluminum, soft tissue fillers (see Table 94.5)
Pseudolymphomatous reaction	Aluminum, tattoo inks
Photoallergic eczematous reaction	Tattoo ink containing cadmium sulfide (yellow), cadmium selenide (red), or azo dyes (yellow, red)

*Often a delayed onset (years).

Table 94.2 Clinical presentations of foreign body reactions.

FOREIGN BODY REACTIONS TO INORGANIC AND METALLIC COMPOUNDS

Tattoo

A tattoo may occur accidentally or deliberately for cosmetic and decorative purposes. Accidental tattooing results from unintentional deposition of exogenous pigmented substances such as asphalt, carbon, or graphite (pencils) within injured skin (Fig. 94.5). Automobile, bicycle, and skating accidents as well as puncture wounds are the most common causes of traumatic tattoos. In decorative tattooing, the pigment is introduced into the dermis via needles or a tattoo gun to create various designs, group-identity symbols, or writings. Cosmetic tattoos are also done to define the contours of lips and eyebrows, permanently replace eyeliner, make eyebrows appear fuller (via microblading), or camouflage an abnormality in skin color. An iatrogenic tattoo may remain after the use of ferrous subsulfate (Monsel's solution) for hemostasis. Other hemostatic agents, e.g. aluminum chloride, may cause a foreign body reaction histologically (see below), but do not lead to discoloration of the skin.

Decorative tattoos often contain a number of pigments that are combined to create different hues, but the composition of tattoo inks has not been standardized. The pigments may be inorganic salts of metals, such as mercury in cinnabar (red, becoming historical), cobalt

Downloaded for Anonymous User (n/a) at Egyptian Knowledge Bank from ClinicalKey.com by Elsevier on March 10, 2024. For personal use only. No other uses without permission. Copyright ©2024. Elsevier Inc. All rights reserved.

CLINICAL AND HISTOPATHOLOGIC FEATURES OF FOREIGN BODY REACTIONS				
Foreign body	**Clinical presentations**	**Histologic reaction patterns**	**Other distinctive features**	**Birefringent**
Tattoo inks	Erythema, induration, papules, nodules	Foreign body or (with certain dyes) sarcoidal granulomas‡ Pseudolymphoma	Pigment granules scattered throughout the infiltrate, extra- and intracellular (macrophages)	
	Lichenoid papules and plaques	Lichenoid dermatitis		
	Eczematous dermatitis (includes allergic* and photo-allergic reactions†)‡	Spongiotic dermatitis		
	Verrucous papules and plaques	Pseudoepitheliomatous hyperplasia		
Silica	Nodules, indurated plaques within scar Disseminated papules (blast injuries) Prolonged incubation period	Granulomas (sarcoidal > foreign body)	Colorless crystals, extra- and intracellular	√
Talc	Sarcoid-like papules Thickening and erythema of an old scar Involvement of intertriginous zones, iv injection sites Umbilical stumps	Sarcoidal or foreign body granulomas	Needle-shaped or round talc crystals: clear, blue–green, or yellow–brown	√
	Pyogenic granuloma-like	Pyogenic granuloma-like		
Zirconium	Persistent, soft, brownish papules Involvement of axillary vault	Sarcoidal granulomas		
Beryllium, local cutaneous reaction	Nodule, ulcer (historical)	Caseating granulomas		
Beryllium, systemic	Widely scattered papules (<1% of cases)	Sarcoidal granulomas		
Aluminum	Persistent subcutaneous nodules at injection site	Granulomas with peripheral lymphocytes and eosinophils Pseudolymphoma	Basophilic granular material within the cytoplasm of histiocytes	
Zinc	Furuncles at injection sites	Early: dense neutrophilic infiltrate Late: granulomas and fibrosis	Rhomboidal crystals	√
Starch	Papules, nodules	Foreign body granulomas	Ovoid basophilic starch granules PAS-positive	√ ("Maltese cross"-like appearance)
Cactus spines	Dome-shaped, skin-colored papules with a central black dot	Early: neutrophils Late: sarcoidal or foreign body granulomas	Spines, extra- and intra-cellular (giant cells) PAS-positive	√
Jellyfish, corals, sea urchin spines	Pruritic lichenoid papules and plaques (onset 2–3 weeks after exposure) Linear, zig-zag and whip-like (flagellate) patterns of erythema/edema (early), hyperpigmentation or lichenoid papules (late)	Lichenoid dermatitis	Calcite crystals (sea urchin spines)	√ (sea urchin spines)
Keratin	Pseudofolliculitis/acne keloidalis	Foreign body granulomas	Other inflammatory cells	√
	Pyogenic granuloma-like lesions (ingrown nails) Pilonidal sinus	Pyogenic granuloma-like		
Intralesional corticosteroids	Skin-colored to yellow–white papules or nodules develop at the site of a previous intralesional injection of corticosteroid The incubation period varies between weeks to months	Foreign body granulomas	Pale bluish material in H&E-stained sections	
Suture	Wound appears inflamed, red, edematous (or develops papules or nodules) and opens to form a fistula	Foreign body granulomas		√

*May also be due to nickel contained in the tattoo gun or preservatives within the tattoo mixture.
†May be associated with a change in the original tattoo color.
‡Allergic reactions most commonly develop within areas of red color and sarcoidal reactions within areas of black color; Rush phenomenon represents the sudden appearance of sarcoidal reactions in multiple tattoos following a reaction in one of them.

Table 94.3 Clinical and histopathologic features of foreign body reactions. The order of the entities in this table corresponds to that in the text. Injectable soft tissue fillers are reviewed in Table 94.5. Energy-dispersive X-ray analysis (EDXA) or laser-induced breakdown spectroscopy can be used to detect tattoo inks, silica, talc, zirconium, aluminum, and zinc. iv, intravenous; PAS, periodic acid Schiff.

(blue), chromium (green), cadmium (yellow, red), ferric hydrate (sienna) and manganese (purple), or organic preparations.

Clinical features

Foreign body reactions may occur within a few weeks of the tattoo placement, but have been reported decades later[16]. Most commonly, erythematous papules, nodules, or plaques are seen (Fig. 94.6), but lesions may be verrucous, lichenoid, pseudolymphomatous, or eczematous. The reactions are usually confined to the site of the tattoo, with the degree of tenderness and erythema reflecting the intensity of the associated inflammation. "Allergic" reactions most frequently occur within the red-colored areas of the tattoo (Fig. 94.7)[13], while sarcoidal

Downloaded for Anonymous User (n/a) at Egyptian Knowledge Bank from ClinicalKey.com by Elsevier on March 10, 2024. For personal use only. No other uses without permission. Copyright ©2024. Elsevier Inc. All rights reserved.

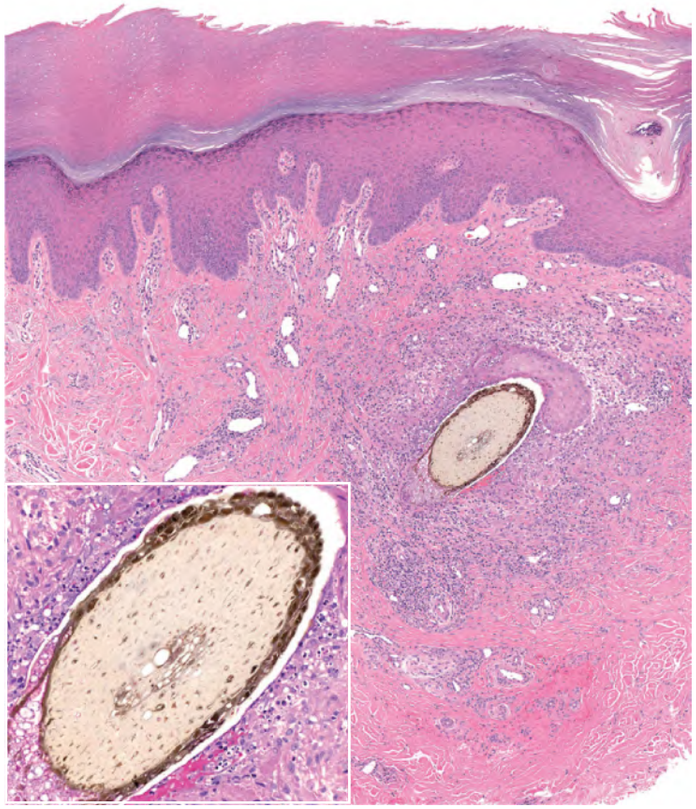

Fig. 94.3 Granulomatous foreign body reaction to implanted organic material in acral volar skin. A plant is the source of the foreign body and the latter is surrounded by a granulomatous reaction as well as neutrophils, lymphocytes, and cellular debris (inset). Superior to the foreign body is a portion of an epidermal cyst due to implantation of epidermal fragments into the dermis. *Courtesy Lorenzo Cerroni, MD.*

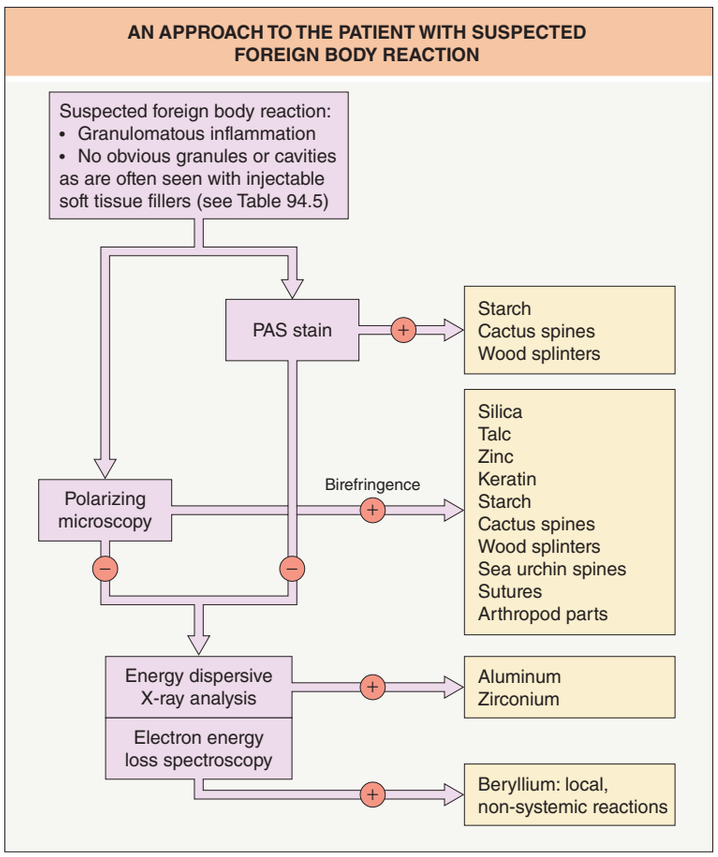

Fig. 94.4 An approach to the patient with suspected foreign body reaction. PAS, periodic acid Schiff.

Fig. 94.5 Traumatic tattoo of the eyelid due to asphalt following a motor vehicle accident. This type of tattoo responds favorably to Q-switched laser therapy.

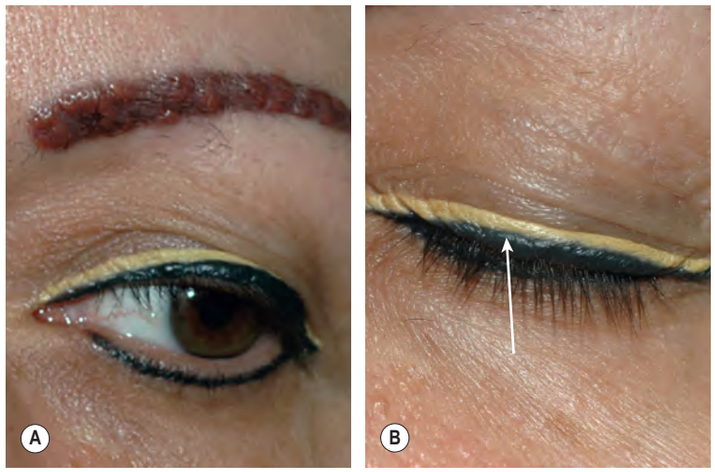

Fig. 94.6 Foreign body reaction to cosmetic tattoos. A Multiple erythematous papules within the eyebrow. **B** Small papules within black eyeliner (arrow). *Courtesy Luis Requena, MD.*

Fig. 94.7 Granulomatous reaction within the red portions of a tattoo. Over the past several years, cinnabar (mercuric sulfide) has been gradually replaced by cadmium selenide (cadmium red), ferric hydrate (sienna), and organic compounds. *Courtesy Lorenzo Cerroni, MD.*

Downloaded for Anonymous User (n/a) at Egyptian Knowledge Bank from ClinicalKey.com by Elsevier on March 10, 2024. For personal use only. No other uses without permission. Copyright ©2024. Elsevier Inc. All rights reserved.

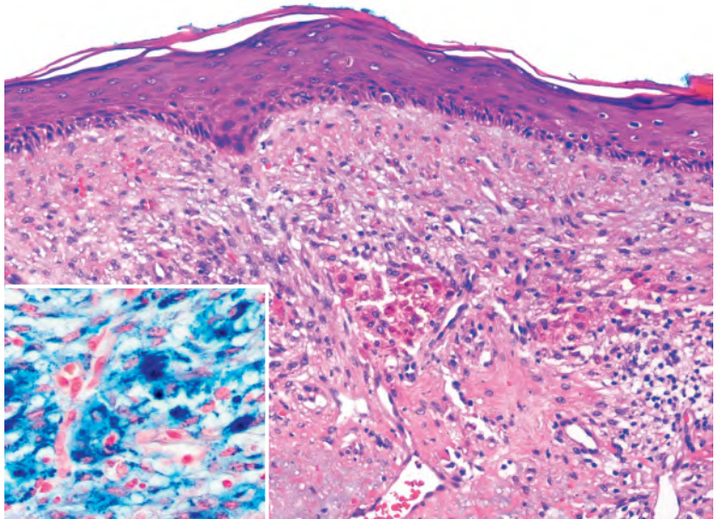

Fig. 94.8 Ferrous subsulfate (Monsel's solution) – iatrogenic tattoo and granulomatous reaction. Coarse granular brown pigment is seen within macrophages and between collagen fibers. The pigment is positive with Perls' stain (inset).
Courtesy Luis Requena, MD.

reactions favor sites of black color. In some patients, granulomatous papulonodules within a tattoo can be a manifestation of cutaneous or systemic sarcoidosis[17]. Rarely, a photoallergic reaction, presenting as pruritic, inflamed nodules, occurs in red or yellow tattoos containing cadmium sulfide following exposure to UV light[16].

Verrucous lesions and pseudoepitheliomatous hyperplasia can also develop within tattoos and may be misdiagnosed as human papillomavirus (HPV) infection or squamous cell carcinoma (SCC). The development of keratoacanthomas or SCCs within tattoos is rare. Tattoo pigments may migrate to the regional lymph nodes and at the time of lymph node sampling may clinically mimic metastatic melanoma[13,18].

Development of inflammation within older tattoos is occasionally triggered by a new tattoo that contains the same pigments. In the Rush phenomenon, granulomatous papulonodules initially develop in the new tattoo then within older tattoos, with sarcoidosis representing a risk factor[17].

Pathology

Different patterns of an inflammatory response can be elicited, including sarcoidal, foreign body granulomatous, lichenoid, eczematous, and pseudolymphomatous[13]. The majority of tattoo pigments appear black in H&E-stained sections, regardless of the color of the pigment (see Fig. 72.23B). Occasionally, colors other than black are seen (see below)[19]. The pigment is deposited in the upper and mid dermis, both extracellularly between collagen bundles and around blood vessels as well as a smaller amount within the cytoplasm of macrophages.

The pigment deposits in professional tattoos are relatively small and homogeneous in size and shape, while in traumatic tattoos they are larger and vary in size and shape[14]. Coarse, granular brown pigment within macrophages and between collagen fibers are seen in iatrogenic tattoos due to ferrous subsulfate (Monsel's solution; Fig. 94.8).

Diagnosis and differential diagnosis

The presence of inflammatory lesions confined to the site of a tattoo suggests the diagnosis. Inoculation of certain infectious agents (e.g. atypical mycobacteria) may mimic pigment-induced inflammation within a tattoo (Table 94.4). In addition to hypertrophic scars and keloids, unrelated benign and malignant tumors can also develop within tattoos.

Identification of the causative pigment is generally unnecessary unless further tattooing is anticipated. Other causes of dermal pigmentation include melanin, hemosiderin, lipofuscin, exogenous ochronosis, silver, gold, minocycline, amiodarone, and chlorpromazine. Special stains to identify melanin and iron (hemosiderin) may be useful (see Ch. 0).

INFECTIONS AND INFLAMMATORY DERMATOSES WITHIN TATTOOS	
Disorder	**Examples**
Infections (reflecting inoculation)	Streptococcal, staphylococcal; atypical mycobacteria (mycobacteria other than tuberculosis); HPV, molluscum contagiosum, HSV
Reactions to pigments	Eczematous, lichenoid, granulomatous foreign body reaction, sarcoidal*, pseudolymphomatous, pseudoepitheliomatous, photoallergic
Koebner phenomenon	Psoriasis, lichen planus, sarcoidosis
Thermal burn induced by MRI	Favors pigments that contain iron oxide
*Evaluate patient for sarcoidosis.	

Table 94.4 Infections and inflammatory dermatoses within tattoos. Systemic infections (e.g. hepatitis C virus, hepatitis B virus, tetanus) have also been reported following tattoo placement. HPV, human papillomavirus; HSV, herpes simplex virus; MRI, magnetic resonance imaging.

Treatment

Topical or intralesional corticosteroids can be used to treat inflamed tattoos. If injections do not lead to significant improvement, surgical excision, if feasible, to remove the inciting pigment is an option. Q-switched and picosecond lasers are commonly employed to remove the various pigments in tattoos (see Fig. 137.16 & Table 137.4)[18], but it is recommended that laser therapy be limited to non-inflamed tattoos[20]. There are reports of systemic reactions, presumably due to the release of pigment from macrophages, following laser therapy[21] and inflamed tattoos may be at greater risk for this side effect. Anecdotally, hydroxychloroquine, tetracyclines, and allopurinol as well as systemic corticosteroids have been used to treat resistant cases.

Paraffin

Paraffin, being a mineral oil, is not hydrolyzed by tissue lipases and is treated by the body as a foreign substance. Augmentation of body contour by local injection of paraffin, although banned in most countries, is still performed in some regions of the world and is mostly done by non-medical personnel. Accidental paraffinoma of the orbit and palpebra has been reported following intraoperative placement of paraffin-impregnated gauze packs within the nasal cavity[5].

Clinical features

In those cases due to injected paraffin, the genitalia, buttocks, and breast are the most common sites of involvement. Penile paraffinomas, also referred to as sclerosing lipogranulomas of the penis, can lead to significant deformity (Fig. 94.9A). Clinically, non-tender firm nodules and indurated plaques are seen, sometimes with ulceration or abscess formation and involvement of subcutaneous tissue (see Ch. 100). The interval between the time of injection and the development of lesions varies from weeks to decades.

Pathology

The dermis shows a characteristic "Swiss cheese" appearance due to the presence of numerous ovoid or round cavities where the paraffin resided prior to processing (Fig. 94.9B). Between the cavities, there is fibrotic connective tissue and a cellular infiltrate composed of macrophages, variable numbers of multinucleated foreign body giant cells, and lymphocytes. Some of the macrophages have foamy cytoplasm. In specially processed tissue, the foreign material stains with fat stains[22], although less intensely than neutral fats, helping to differentiate paraffinoma from reactions to silicone, which also have numerous cavities but negative fat stains.

Treatment

Excision with appropriate tissue reconstruction is the only means of therapy.

Downloaded for Anonymous User (n/a) at Egyptian Knowledge Bank from ClinicalKey.com by Elsevier on March 10, 2024. For personal use only. No other uses without permission. Copyright ©2024. Elsevier Inc. All rights reserved.

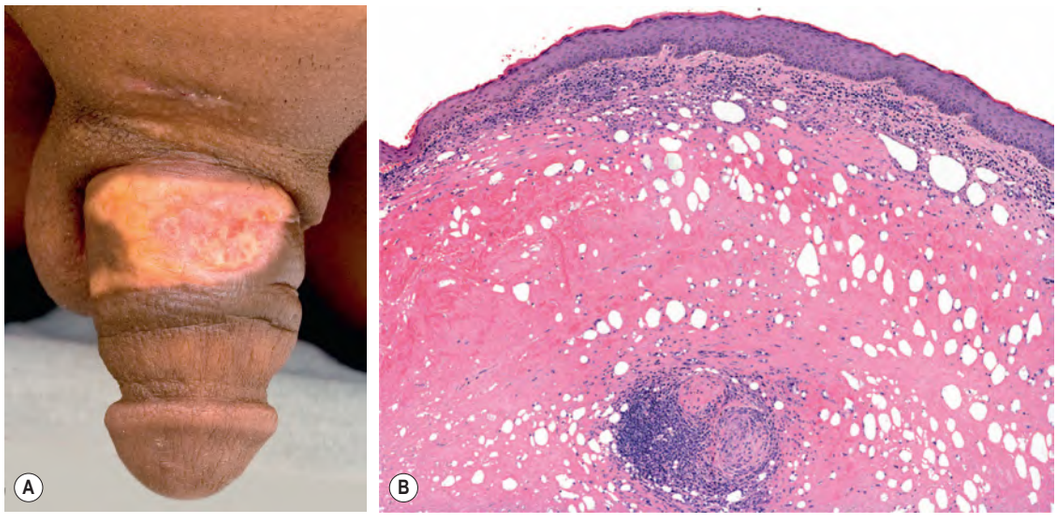

Fig. 94.9 Sclerosing lipogranuloma of the penis. A The penis was injected with paraffin in order to relieve urinary retention following a motorbike accident, and an ulcerated, indurated yellow plaque with telangiectasias developed at the site. **B** Histologic examination showed sclerosis as well as multiple circular and oval empty spaces within the dermis. *Courtesy Glen Foxton, MD and Clare Tait, MD.*

Silicone

Silicone (polydimethyl siloxane), in a liquid, gel, or solid form, is used for tissue augmentation. While silicone is generally regarded as an inert substance, in some patients its use has been followed by foreign body reactions.

Clinical features

Silicone gel-filled implants are widely used for breast augmentation as well as reconstruction after mastectomy and leakage due to permeability loss or rupture can occur. Silicone injections and implants have also been employed for body and facial contour augmentation, including correcting HIV-related lipoatrophy. When a cutaneous foreign body reaction occurs, nodules and plaques develop at the site of injection or placement after a period of months to years. Skin lesions also appear at distant sites, reflecting the tendency for silicone to migrate, including in a dependent, gravity-driven direction. With progression, sclerosis and ulcerations can be seen. Whether the immune system is recognizing the silicone itself versus additives or contaminants including microbes remains speculative[23].

In a recent systematic review, hypercalcemia with renal failure was noted in association with silicone-induced foreign body granulomas and, to lesser extent, polymethylmethacrylate-, paraffin-, and mineral oil-induced foreign body granulomas[24]. An increased risk of autoimmune connective tissue diseases (e.g. Sjögren syndrome, systemic sclerosis, rheumatoid arthritis) in patients with silicone breast implants has been observed in some, but not most, studies[25]. Agreement does exist that textured breast implants, both saline and silicone, are associated with anaplastic large cell lymphoma of the breast.

Pathology

A biopsy specimen is critical to establishing the diagnosis. Histologic sections have a multivacuolated appearance due to the presence of silicone-filled cavities surrounded by histiocytes, lymphocytes, and eosinophils. The histiocytes may be foamy or multinucleated. Fibrous tissue within the areas separating the cavities is also seen. In contrast to paraffinomas, the cavity contents do not stain with lipid stains. Occasionally, silicone granulomas can mimic a low-grade liposarcoma.

Treatment

Excision of persistent symptomatic lesions is recommended.

Silica

Wounds or penetrating injuries accidentally contaminated with silica (silicon dioxide) contained in sand, soil, rocks, and glass may be followed some years later by the formation of a foreign body reaction. The period between inoculation and development of a reaction may be as long as 25 years. This extended "incubation" period is due to the very slow release of colloidal silica (the only form capable of inciting a reaction) from the large particles of silica introduced into the body[26]. Reactions to silica are thought to be due to a delayed-type hypersensitivity response.

Clinical features

At first, the wound heals, but then papules, nodules, or indurated plaques develop within the scar years later. Multiple disseminated lesions may follow trauma produced by the explosion of land mines and bombs[26]. Patients with sarcoidosis may be at increased risk for immunologic responses to silica[27].

Pathology

The dermis contains multiple nodular aggregates of granulomas, usually sarcoidal and less often foreign body, separated by strands of connective tissue. Langhans- and foreign body-type giant cells are usually numerous in both types of granuloma. Colorless crystals may be observed within the cytoplasm of the giant cells or lying free in the interstitium. These bodies are birefringent when examined with polarized microscopy.

Differential diagnosis

Granulomatous lesions occurring at the site of an old scar may mimic cutaneous sarcoidosis clinically and histologically[28]. However, the presence of foreign material within a sarcoidal granuloma does not exclude sarcoidosis, given the attraction of sarcoidosis to existing scars. Examination under polarized light will identify silica crystals.

Treatment

Excision of persistent symptomatic lesions is recommended. Spontaneous resolution of silica granulomas, although reported, is exceptional.

Talc

Talc (hydrous magnesium silicate) is a common cause of foreign body granulomas given its presence in dusting, antifungal, and antibiotic powders. In addition, it is still preferred by some surgeons as a lubricant for surgical gloves. Talc can therefore contaminate wounds, erosions, and umbilical stumps, or it may enter the skin via abrasions and fissures, particularly in intertriginous zones in obese individuals who apply talc powder liberally[29].

Individuals with substance use disorder who inject solutions intravenously or subcutaneously that contain crushed tablets may also develop foreign body reactions to talc as talc is a common filler in tablets. The foreign body reactions may arise at injection sites or at distant sites (e.g. pulmonary intravascular talcosis)[30].

Downloaded for Anonymous User (n/a) at Egyptian Knowledge Bank from ClinicalKey.com by Elsevier on March 10, 2024. For personal use only. No other uses without permission. Copyright ©2024. Elsevier Inc. All rights reserved.

Clinical features

As with reactions to other forms of silica, the lesions usually take a long time to appear. The clinical appearance is varied: it may take the form of erythematous papules and nodules or simply thickening and erythema of an old scar, similar to the range of findings in sarcoidosis. Rarely lesions may resemble a pyogenic granuloma. Despite the long latency period, the diagnosis should be considered, especially when lesions appear in certain sites, e.g. the umbilicus in infants, inguinal area in patients with a history of intertrigo, injection sites in those with a history of intravenous drug use.

Pathology

The histologic features may be similar to those of sarcoidosis or non-caseating tuberculosis. Alternatively, there may be granulomatous inflammation consisting of histiocytes and foreign body giant cells. A few of these cells may contain clear, blue–green, or yellow–brown, needle-shaped or round crystals. Under polarized light, talc crystals are birefringent. A picture simulating a pyogenic granuloma plus giant cells has also been described[5].

Treatment

Excision of persistent symptomatic lesions is recommended.

Zirconium

Some zirconium salts were once components of antiperspirant preparations as well as over-the-counter preparations used in the treatment of allergic contact dermatitis. Sodium zirconium lactate was the first salt incriminated as a cause of foreign body reactions and while banned in the late 1970s, it was replaced by aluminum–zirconium complexes. Subsequently, zirconium oxide and aluminum–zirconium complex were shown to be capable of producing the same reaction. Development of foreign body granulomas represents a delayed-type hypersensitivity reaction to zirconium[6].

In sensitized individuals, persistent, soft, red–brown papules appear in areas to which zirconium-containing preparations were applied. The axillary skin is the most frequently affected site.

Histologically, non-caseating granulomas resembling a sarcoidal reaction are seen[6]. The small size of the zirconium particles does not allow their detection with polarized light microscopy; however, energy-dispersive X-ray analysis can prove their presence.

Beryllium

Chronic beryllium disease is an immunologically mediated occupational disease, primarily affecting workers exposed to beryllium during its manufacture and recycling or in alloy production. Inhalation of beryllium particles was thought to be the source of exposure, but more recent evidence points to both penetration of fine particles (<1 micron) through intact skin, as well as inhalation, as possible routes[31]. In systemic berylliosis, the primary pathology is in the lung and skin involvement is rare (<1%). The cutaneous granulomas of systemic berylliosis consist of widely scattered papules with no secondary changes.

Histologically, cutaneous lesions of systemic berylliosis are indistinguishable from sarcoidosis. In the past, when beryllium was used in the manufacture of fluorescent light bulbs, local cutaneous berylliosis was noted to have a caseating tuberculoid pattern. In systemic berylliosis, bronchioalveolar lavage is recommended for diagnosis.

Aluminum

Rare hypersensitivity reactions to the aluminum adjuvant in vaccines and hyposensitization immunotherapy do occur. Persistent subcutaneous granulomatous nodules can appear at the sites of injection several months after vaccination[32]. Histologically, a central zone of degenerated collagen is surrounded by a rim of both histiocytes, whose cytoplasm contains bluish-grey granules, and lymphoid aggregates, some of which form germinal centers[32,33]. There are also abundant eosinophils. Special stains (e.g. staining for aluminon in which the aluminum appears red) may make aluminum particles more evident. Of note, application of *topical* aluminum chloride for hemostasis can result in the presence of basophilic granules of varying size and shape within the cytoplasm of macrophages[34].

Zinc

A zinc-induced granuloma at the site of an injection is a rare complication of zinc-containing insulin[35]. Sterile furuncles develop at the injection sites and eventually heal with atrophic scars. Histologically, an initial stage characterized by a dense neutrophilic infiltrate is followed by granuloma formation that ends in fibrosis. By polarizing microscopy, birefringent rhomboid crystals are seen.

Treatment

Zirconium, beryllium, aluminum, and zinc granulomas may be surgically excised if they are symptomatic.

REACTIONS TO ORGANIC AND BIOLOGIC PRODUCTS

Starch

Granulomas may result from the contamination of wounds with starch used as a lubricant for surgical gloves.

Pathology

Foreign body granulomas with multinucleated giant cells are seen. Starch granules appear as ovoid basophilic structures. They stain positively with periodic acid Schiff (PAS) and with polarized light are birefringent with a characteristic "Maltese cross"-like appearance[36].

Cactus Spines

Accidental implantation of cactus spines into the skin results from contact with cacti in gardens and fields. Occupational exposure occurs in persons peeling and selling prickly pear fruit, especially in the Middle East and Latin America. Most of the reported cases are due to contact with the genus *Opuntia*[37].

At the time of injury, acute inflammation occurs and then, in some patients, eventually evolves into a typical foreign body reaction. The lesions occur primarily on the hands and fingers as clusters of dome-shaped, skin-colored papules with a central black dot, sometimes called "Sabra dermatitis" (see Ch. 17). This may resemble scabies or fiberglass dermatitis.

Pathology

Foreign body granulomas occupy the entire dermis and surround the spine fragments, which stain intensely red with PAS stain[14,37]. Wood splinters and thorns of other plant origin have a similar suppurative or granulomatous reaction. However, most splinters appear brown with a geometric pattern of cell walls. Fungal hyphae may be present within the plant material, but they seldom invade the surrounding dermis in a healthy host.

Cnidaria (Coelenterata) – Jellyfish, Corals

Members of the phylum Cnidaria (Coelenterata) include jellyfish, corals, and sea anemones (see Ch. 85). Almost all cnidarians possess nematocysts which contain highly coiled, hollow harpoon-like structures that inject a toxin into the skin upon contact.

Clinical features

Jellyfish and coral stings elicit similar cutaneous reactions: an early primary irritant toxic reaction in all exposed persons, and a delayed-type hypersensitivity reaction in a small percentage. A sharp burning pain is felt and, within minutes, the affected area becomes erythematous and edematous and may form blisters (see Fig. 85.20). The acute response may be accompanied by an immediate-type hypersensitivity reaction including urticaria, angioedema, and even anaphylaxis. The lesions resolve, leaving postinflammatory hyperpigmentation in a streaky flagellate fashion corresponding to where the coral or jellyfish brushed the skin. In some individuals, new lesions appear a

Downloaded for Anonymous User (n/a) at Egyptian Knowledge Bank from ClinicalKey.com by Elsevier on March 10, 2024. For personal use only. No other uses without permission. Copyright ©2024. Elsevier Inc. All rights reserved.

few weeks later at previously involved sites (average 3 weeks)[8]. The latter are severely pruritic, shiny, lichenoid papules and plaques and are arranged in a number of patterns, including linear, zig-zag, and whip-like.

Pathology

The lesions that comprise the delayed response have a lichenoid tissue reaction.

Treatment

First aid includes soaking the site in hot, but not scalding, water (denatures proteins). Subsequent use of topical potent corticosteroids, antihistamines, and systemic corticosteroids is controversial. Treatment of acute reactions is reviewed in Chapter 85. Intralesional corticosteroids are the most effective therapy for delayed-type hypersensitivity reactions.

Keratin

Keratin, normally sequestered from the body's immune surveillance by the surrounding epithelium, is treated as foreign if it directly contacts the dermis. This may occur as a result of the rupture of hair follicles, epidermoid cysts, or acne lesions as well as from external keratin sources such as ingrown nails or ingrown hairs; the latter occur in pseudofolliculitis and in pilonidal sinuses. Another source is accidental entry of hairs into interdigital skin, especially in barbers, hairdressers, and dog groomers.

Pseudofolliculitis barbae

In pseudofolliculitis barbae, there is a foreign body inflammatory reaction surrounding a hair that has been previously shaved or plucked (see Ch. 38). This condition affects mainly those with curly hair, with an incidence of more than 50% amongst Black individuals. Certain inherent properties of the hairs in affected individuals, in particular a curled flattened elliptical shape, play an important pathogenic role. Because the shaft is curved, it grows back toward the skin surface. When shaved, the flattened elliptical hair shaft develops a pointed tip, which facilitates re-entry of the hair into the skin (extrafollicular penetration). Transfollicular penetration can also occur (see Fig. 38.10). A foreign body reaction to keratin results in the development of inflammatory papules and pustules that are often followed by hyperpigmentation or small keloidal scars (see Fig. 38.11)[11].

Pseudofolliculitis also affects women or men who regularly remove hair from the pubic region, axillae, and legs by plucking or shaving. Papules containing embedded hairs, pustules, and crusted papules develop in affected areas, often resolving with significant postinflammatory hyperpigmentation.

Treatment

Apart from cessation of shaving or laser epilation of the affected areas, nearly all therapeutic modalities are unrewarding. For further details, see Chapters 38 and 137.

Pilonidal sinus

Most cases of pilonidal sinus occur in the sacrococcygeal region (see Ch. 38). Much less often, it is seen in the umbilical region[38], and, rarely, interdigitally in barbers[39].

Sacrococcygeal pilonidal sinuses may be asymptomatic (debris-filled pit) or present as a draining sinus or an acute abscess. The condition is more common in young men. There is often an underlying cyst with associated granulation tissue, fibrosis, and frequently tufts of hairs. Excisional specimens reveal a sinus tract extending into the dermis and subcutaneous tissue, surrounded by chronic inflammation. Hairs are found in the sinuses in three-quarters of the cases[40].

Small, asymptomatic or slightly tender, openings in the interdigital web spaces of the hands have been observed in barbers, hairdressers, and dog groomers. When these individuals cut hair while wearing sandals, lesions can develop in the web spaces of the feet as well. Penetration of short hairs into the interdigital spaces incites an inflammatory foreign body granuloma. The clinical course is usually self-limited but can be complicated by repeated infections, which may require surgical excision of the involved area[39]. Histologically, a sinus tract lined by epidermis and containing one or several hairs is seen. Hairs extending deeper than the sinus tract incite a foreign body reaction.

INJECTABLE SOFT TISSUE FILLERS

With the exception of autologous fat, all injectable soft tissue fillers, resorbable or non-resorbable, represent foreign bodies and therefore have the potential to cause foreign body reactions (Figs. 94.10 & 94.11; see Ch. 158). Two types of reactions have been reported: non-immunogenic and immunogenic. The former is characterized by localized tissue necrosis, which occurs shortly after implantation, and such reactions are probably the result of local vascular interruption; two-thirds of local necrotic events occur in the glabellar area[41]. Depending upon the particular filler, associated foreign body reactions can range from relatively common (e.g. paraffin) to rare (e.g. hyaluronic acid)[42]. Paraffin and silicone are discussed above and the histopathologic features of inflammatory reactions to various fillers are outlined in Table 94.5[41]. Foreign body reactions usually appear within 1–2 years after injection, and spontaneous resolution occurs in the majority of cases within a year, while the remainder have lesions that wax and wane[43,44].

Hyaluronic Acid

Currently, hyaluronic acid is the most commonly utilized injectable soft tissue filler, in part because the incidence of foreign body reactions is much lower (0.4%) than that reported for bovine collagen (3%–4%)[42]. When a reaction does occur, the injected site becomes firm, tender, edematous, and erythematous, and an abscess may form. This reaction responds to intralesional injections of corticosteroid or hyaluronidase (see Ch. 158)[44], although some patients may be willing to wait for spontaneous resolution which can occur over several months.

Bovine Collagen

In general, bovine collagen alone has been replaced by other less antigenic soft tissue fillers, especially hyaluronic acid. However, there are fillers in which bovine collagen is combined with polymethyl methacrylate microspheres, e.g. Bellafill® (formerly Artefill®). Despite negative skin testing (which is required prior to treatment), a small proportion of patients injected with bovine collagen still develop a local reaction (see Fig. 94.1)[44].

Fig. 94.10 Granulomatous reaction due to silicone injections. The procedure was performed in a beauty salon for cosmetic purposes.

Downloaded for Anonymous User (n/a) at Egyptian Knowledge Bank from ClinicalKey.com by Elsevier on March 10, 2024. For personal use only. No other uses without permission. Copyright ©2024. Elsevier Inc. All rights reserved.

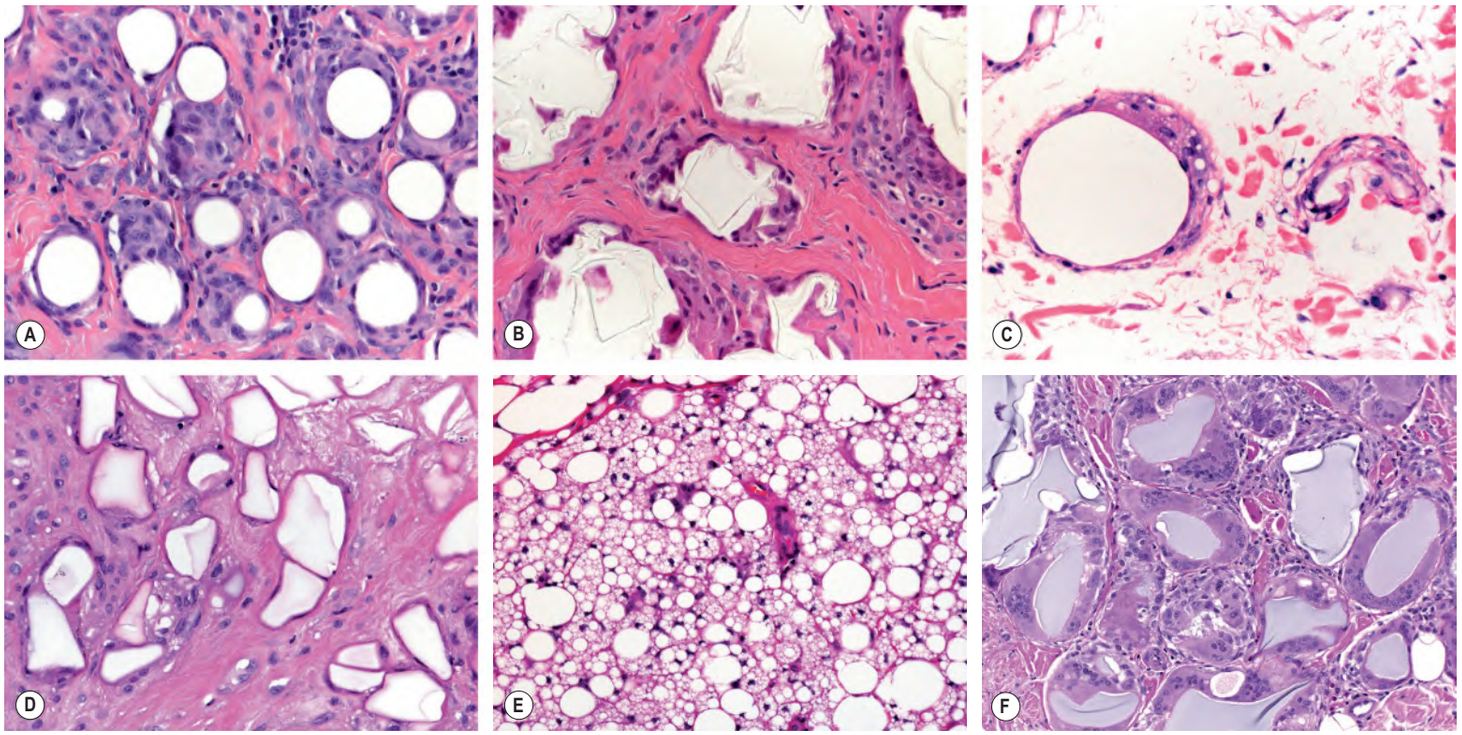

Fig. 94.11 Histopathologic features of granulomatous reactions to different injectable soft tissue fillers. A Multiple uniform vacuoles within an area of granulomatous inflammation due to polymethylmethacrylate microspheres suspended in bovine collagen (Bellafill®, previously known as ArteFill®). **B** Translucent, polygonal and irregularly shaped deposits plus fibrosis and granulomatous inflammation due to silicone elastomer particles and polyvinylpyrrolidone (Bioplastique®). **C** Rounded deposits of silicone surrounded by histiocytic giant cells in a granulomatous reaction to silicone that leaked from a breast implant. **D** Light pink to translucent deposits with a prominent rim in addition to fibrosis due to fragments of hydroxyethylmethacrylate/ethylmethacrylate fragments and hyaluronic acid (Dermalive®). **E** In this granulomatous reaction to silicone injected into the lip, the histiocytes have a foamy appearance due to engulfed silicone. **F** Homogeneous blue-gray deposits of hyaluronic acid within multiple foreign body giant cells. *A–D, F, Courtesy Lorenzo Cerroni, MD; E, Courtesy Luis Requena, MD.*

MISCELLANEOUS

Intralesional Corticosteroids

Foreign body reactions to intralesional corticosteroids are quite rare despite the widespread use of this treatment modality. Reactions result from failure of the injected material to disperse in the usual manner or from incomplete absorption, leaving a small residuum that evokes a foreign body reaction[45].

Histologically, pools of granular, lightly stained material surrounded by a histiocytic and foreign body granulomatous infiltrate are seen in the dermis. Cellular reactions are absent around sites of recent injections[45].

Sutures

Nylon and polypropylene sutures used in contemporary surgery are relatively inert (see Ch. 144), but most other materials regularly produce chronic inflammation and granuloma formation (see Fig. 151.19). The incubation period varies from weeks[46] to years[47].

The incision site may appear inflamed, red, and edematous. A sinus tract may develop, through which the suture material is extruded. Inflammation persists until the suture material is totally removed.

Histologically, granulomatous inflammation of various types is seen surrounding suture material: foreign body, histiocytic, palisading, or a combination thereof (see Fig. 94.2)[46,47]. Transepidermal elimination of the suture material occurs[46].

Polyamide "Hair" Implants

In patients with androgenetic alopecia in whom autologous hair transplantation is not feasible (e.g. inadequate donor sites), polyamide "hair" fibers have been used for synthetic scalp hair restoration. Although some authors have reported complications in only ~1% of patients, foreign body reactions are a real risk (Fig. 94.12)[48]. Polyamide fiber hair restoration is not approved in the US.

Fig. 94.12 Foreign body reactions to polyamide synthetic "hair" implantation. In addition to multiple perifollicular granulomas, there is evidence of chronic folliculitis.

Mesotherapy

Mesotherapy involves placement of a pharmacologic substance into the "mesoderm" (dermis and subcutis). For example, injections of deoxycholic acid (Kybella®) have been approved for the reduction of submental fat and may lead to a temporary chemical panniculitis. However, non-standardized combinations such as phosphatidylcholine plus a detergent solvent (e.g. deoxycholic acid) are also used for lipolysis. With

Downloaded for Anonymous User (n/a) at Egyptian Knowledge Bank from ClinicalKey.com by Elsevier on March 10, 2024. For personal use only. No other uses without permission. Copyright ©2024. Elsevier Inc. All rights reserved.

HISTOPATHOLOGIC FEATURES OF INJECTABLE SOFT TISSUE FILLERS		
Category	**Chemical composition**	**Histopathologic features**
Resorbable within months	Hyaluronic acid	• Irregular clusters of basophilic material surrounded by histiocytes and giant cells • Alcian blue stain positive
	Bovine collagen	• Palisading granulomas with foreign body giant cells and eosinophilic bovine collagen in the center of the granulomas • Appearance with polarization differs from human collagen* • IHC – positive staining with anti-bovine collagen type I antibodies
	Human collagen – bioengineered, cadaveric, autologous	• Granulomatous reaction • Appearance with polarization differs from bovine collagen*
Resorbable within years	Hyaluronic acid plus dextranomer microparticles	• Suppurative granulomas surround bluish-grey filamentous material and round, bluish, spherical particles
	Poly-L-lactic acid microspheres plus sodium carboxymethyl-cellulose	• Foreign body granulomas surround fusiform or oval translucent particles • Birefringent under polarized light
	Calcium hydroxylapatite plus carboxymethylcellulose	• Foreign body granulomas surround bluish, rounded particles
Permanent	Paraffin†	• Foreign body granulomas with "Swiss cheese" appearance (Fig. 94.9B) • Positive fat stains (e.g. oil red O) • Detected by IRS
	Silicone oil or silicone gel	• Foreign body granuloma with a multivacuolated appearance (also referred to as "Swiss cheese"; Fig. 94.11C) and histiocytes may be foamy (Fig. 94.11E) • Negative fat stains • Detected by EDXA and in an X-ray, appears radio-opaque
	Silicone particles (100–600 microns) suspended in polyvinylpyrrolidone	• Foreign body reaction with translucent, irregular, non-birefringent particles dispersed in a sclerotic stroma (Fig. 94.11B)
	Polymethylmethacrylate microspheres plus bovine collagen	• Granulomatous infiltrates around vacuolar structures of homogeneous shape and size (Fig. 94.11A)
	Hydroxyethylmethacrylate/ethylmethacrylate fragments in hyaluronic acid	• Foreign body granulomas surround polygonal, irregular, translucent pink structures (Fig. 94.11D)
	Polyacrylamide hydrogel	• Foreign body granulomas surround basophilic, multi-vacuolated material
	Polyalkylimide gel	• Basophilic, amorphous, granular material surrounded by inflammatory infiltrates
	Polyvinylhydroxide microspheres suspended in polyacrylamide gel	• No reports of cutaneous side effects to date; limited local reactions at test sites in volunteers
	Alginates	• Severe granulomatous reaction • Filler material may not be visible or may appear as large, basophilic, oval particles

*Human collagen is birefringent under polarized light and stains green with Masson trichrome stain, whereas bovine collagen is not birefringent with polarized light and stains pale gray–violet with Masson trichrome stain.
†Banned in most countries; also seen after application of paraffin-impregnated gauze packs.

Table 94.5 Histopathologic features of injectable soft tissue fillers. For trade names of the various fillers, see Ch. 158. EDXA, energy dispersive X-ray analysis; IHC, immunohistochemical; IRS, infrared spectrophotometry (non-processed tissue). *Adapted from references 42 & 44.*

these latter combinations, irritant cutaneous necrosis and atypical mycobacterial infections have been observed as well as granulomatous reactions[49]. Lastly, application of moisturizers prior to microneedling for facial rejuvenation can lead to granulomatous reactions[50].

Gouty tophi

Gouty tophi consisting of urate crystals form multiple lobules separated by fibrous septa surrounded by histiocytes and multinucleated foreign body giant cells, resembling a foreign body reaction (see Fig. 48.3). In long-standing tophi, calcium pyrophosphate dehydrate crystals have been detected and they may be dispersed or condensed and present at the edge or inside the tophus lobules. These calcium crystals appear to be a late event and may contribute to the persistence of gout tophi despite success in lowering serum urate levels[51].

Additional figures available in our eBook (see inside front cover for access code).

REFERENCES

1. Del Rosario RN, Barr RJ, Graham BS, Kaneshiro S. Exogenous and endogenous cutaneous anomalies and curiosities. *Am J Dermatopathol*. 2005;27:259–267.
2. Jaworsky C. Analysis of cutaneous foreign bodies. *Clin Dermatol*. 1991;9:157–178.
3. Lammers RL, Magill T. Detection and management of foreign bodies in soft tissue. *Emerg Med Clin North Am*. 1992;10:767–781.
4. Dragu A, Unglaub F, Schwarz S, et al. Foreign body reaction after usage of tissue adhesives for skin closure: a case report and review of the literature. *Arch Orthop Trauma Surg*. 2009;129:167–169.
5. Feldmann R, Harms M, Chavaz P, et al. Orbital and palpebral paraffinoma. *J Am Acad Dermatol*. 1992;26:833–835.
6. Skelton III HG, Smith KJ, Johnson FB, et al. Zirconium granuloma resulting from an aluminum zirconium complex: a previously unrecognized agent in the development of hypersensitivity granulomas. *J Am Acad Dermatol*. 1993;28:874–876.
7. Pagán AJ, Ramakrishnan L. The formation and function of granulomas. *Annu Rev Immunol*. 2018;36:639–665.
8. Azzopardi EA1, Xuereb CB, Iyer S. Pyogenic granuloma as a surrogate indicator of deep seated foreign bodies: a case report. *Cases J*. 2009;2:7354.
9. Hindson C, Foulds I, Cotterill J. Laser therapy of lichenoid red tattoo reaction. *Br J Dermatol*. 1995;133:665–666.
10. Addy JH. Red sea coral contact dermatitis. *Int J Dermatol*. 1991;30:271–273.
11. Halder RM. Pseudofolliculitis barbae and related disorders. *Dermatol Clin*. 1988;6:407–412.
12. Alexis A, Heath CR, Halder RM. Folliculitis keloidalis nuchae and pseudofolliculitis barbae: are prevention and effective treatment within reach? *Dermatol Clin*. 2014;32:183–191.
13. Bassi A, Campolmi P, Cannarozzo G, et al. Tattoo-associated skin reaction: the importance of an early diagnosis and proper treatment. *Biomed Res Int*. 2014;2014:354608.
14. Molina-Ruiz AM, Requena L. Foreign body granulomas. *Dermatol Clin*. 2015;33:497–523.
15. Busser B, Moncayo S, Trichard F, et al. Characterization of foreign materials in paraffin-embedded pathological specimens using in situ multi-elemental imaging with laser spectroscopy. *Mod Pathol*. 2018;31:378–384.

Downloaded for Anonymous User (n/a) at Egyptian Knowledge Bank from ClinicalKey.com by Elsevier on March 10, 2024. For personal use only. No other uses without permission. Copyright ©2024. Elsevier Inc. All rights reserved.

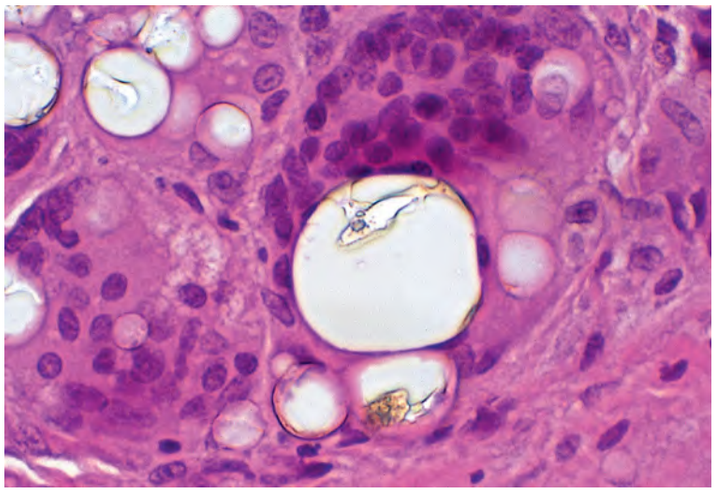

eFig. 94.1 Birefringent foreign body is engulfed by a foreign body-type giant cell with the typical haphazard array of nuclei. *Courtesy Thomas D Horn, MD.*

eFig. 94.3 Granulomatous reaction to the red (cinnabar) portions of a tattoo. Over the past several years, cinnabar (mercuric sulfide) has been gradually replaced by cadmium selenide (cadmium red), ferric hydrate (sienna), and organic compounds. *Courtesy Ronald P. Rapini, MD.*

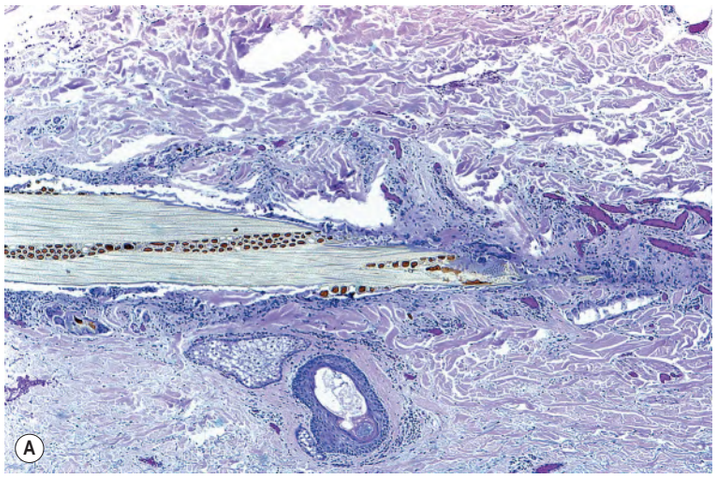

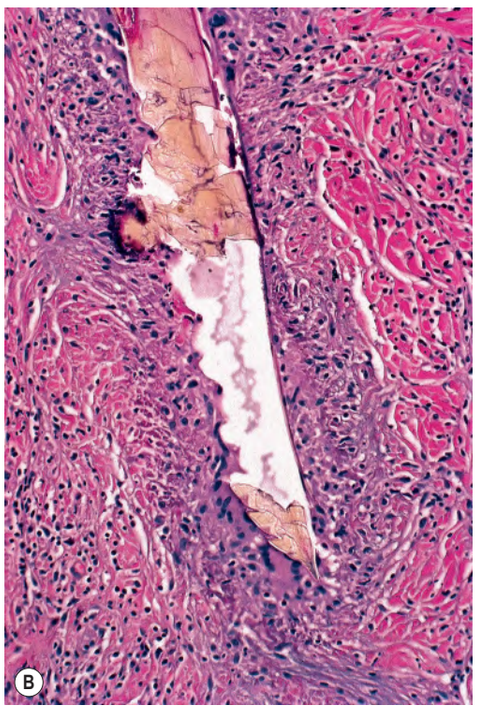

eFig. 94.2 Granulomatous foreign body reactions to implanted organic material. Wood splinter (**A**) versus bee stinger (**B**). Most splinters appear brown with a geometric pattern of cell walls. *A, Courtesy Ronald P. Rapini, MD.*

eFig. 94.4 Coral envenomation. Delayed lichenoid reaction on the calf. The patient accidentally came into contact with a coral reef and developed acute dermatitis that resolved, to be followed 3 weeks later by this severely pruritic eruption that responded favorably to intralesional triamcinolone injection.

Downloaded for Anonymous User (n/a) at Egyptian Knowledge Bank from ClinicalKey.com by Elsevier on March 10, 2024. For personal use only. No other uses without permission. Copyright ©2024. Elsevier Inc. All rights reserved.

eFig. 94.5 Foreign body reaction to silica. *Courtesy Louis A. Fragola Jr, MD.*

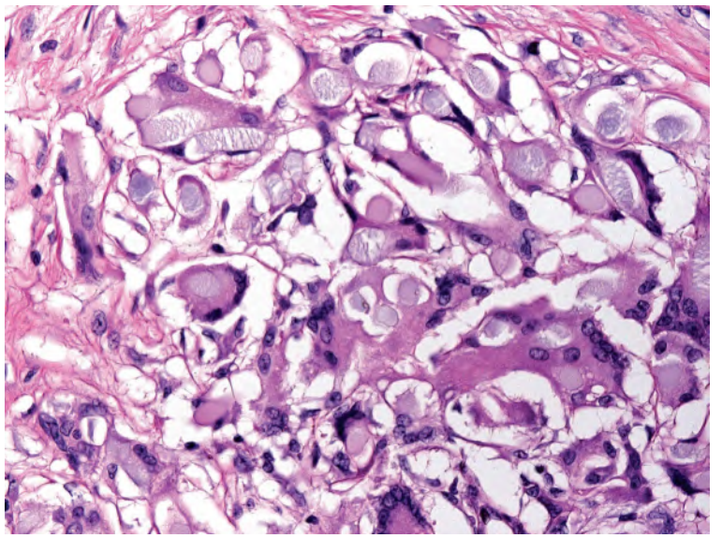

eFig. 94.6 Foreign body reaction to sutures. The foreign bodies have been engulfed by foreign body-type giant cells. *Courtesy Lorenzo Cerroni, MD.*

Downloaded for Anonymous User (n/a) at Egyptian Knowledge Bank from ClinicalKey.com by Elsevier on March 10, 2024. For personal use only. No other uses without permission. Copyright ©2024. Elsevier Inc. All rights reserved.